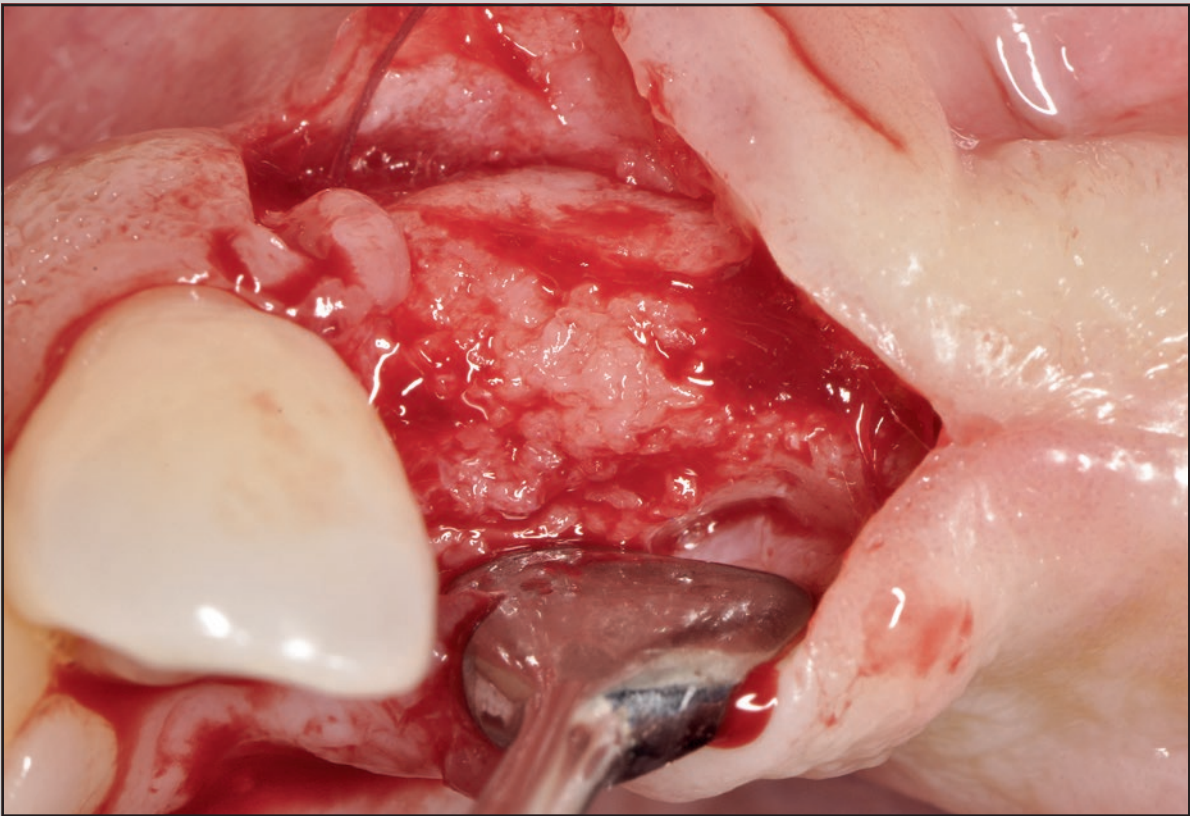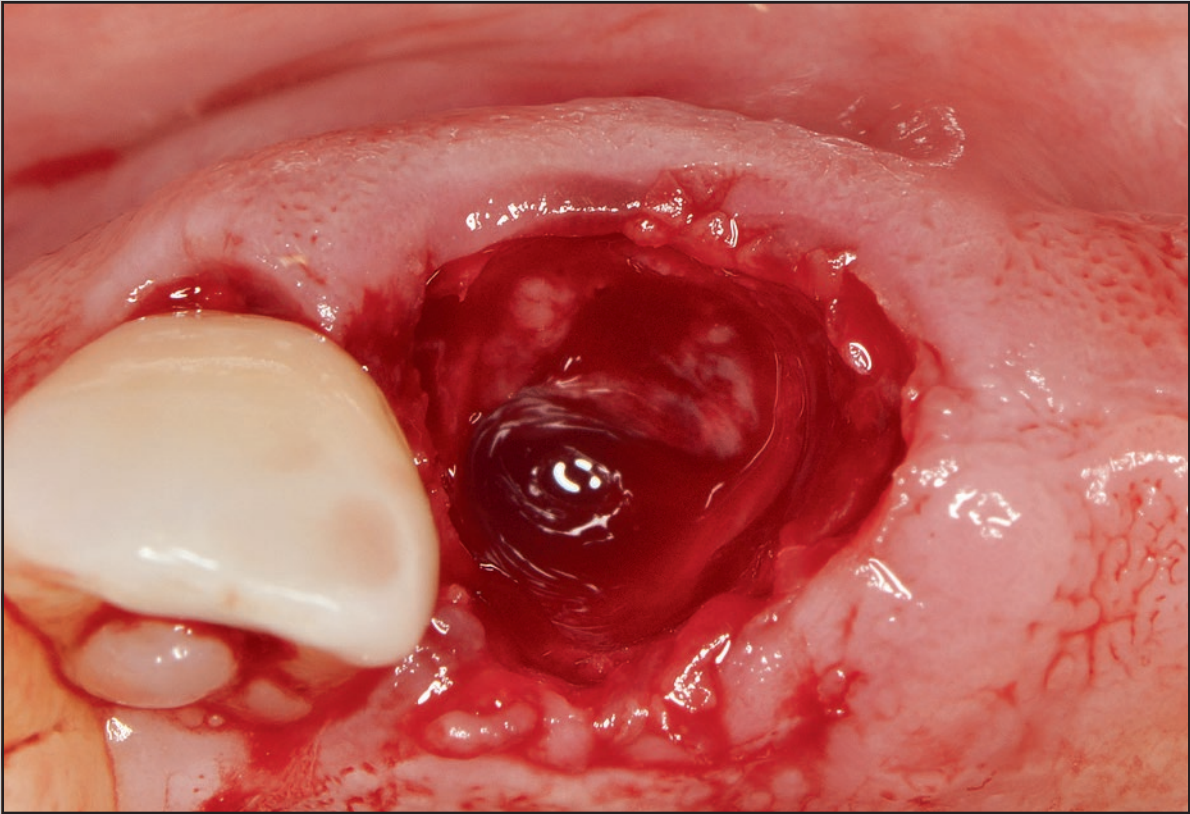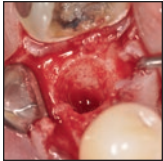


# The Biocompatibility of Cyanoacrylate Tissue Adhesive in Conjunction with a Collagen Membrane for Providing Soft and Hard Tissue Regeneration in Extraction Socket Preservation Procedures



Myron Nevins, DDS<sup>1</sup>  
Gerardo Mendoza-Azpur, MSc<sup>2</sup>  
Nicola De Angelis, DDS, DMSc<sup>3</sup>  
David M. Kim, DDS, DMSc<sup>4</sup>

*This clinical investigation was performed to determine the efficacy of cyanoacrylate tissue adhesive to enhance soft and hard tissue healing of extraction wounds requiring a regenerative effort. Fourteen patients requiring a total of 25 tooth extractions were selected. Twenty sockets were treated with cyanoacrylate tissue adhesive over an exposed collagen barrier membrane without altering the mucogingival junction, while five extraction sockets were allowed to heal by the secondary healing intention as well but without tissue adhesive application. The results were evaluated with emphasis on soft tissue color and form as well as bone surface morphology. All sites received dental implants. There was a clear advantage to using cyanoacrylate tissue adhesive as a protective mechanism over an exposed collagen barrier membrane. Int J Periodontics Restorative Dent 2018;38(suppl):s37–s42. doi: 10.11607/prd.3770*

There is significant knowledge related to the healing of extraction wounds with and without regenerative therapies.<sup>1–8</sup> The use of dental implants to replace elements of the dentition has resulted in the need to protect the bony housing after extraction, so as to develop an esthetic soft tissue enhancement.

A prominent root position is often accompanied by a thin, frail buccal plate that may be damaged during tooth removal, resulting in a deformed edentulous ridge whose bone morphology would require augmentation before an implant placement. Hence, preservation of the alveolus at the time of extraction of prominent roots in the anterior maxilla is crucial to allow optimal implant placement.

A clinical case series investigation was initiated to address the potential protective role of cyanoacrylate tissue adhesive in protecting intentionally exposed collagen barrier membranes in extraction socket preservation procedures. Intentional exposure of the collagen barrier membrane to avoid vertical releasing incisions or change in mucogingival junction has been advocated. Although there have been several clinical and histologic investigations supporting this concept of secondary wound healing over an exposed collagen barrier membrane, not all membranes will have the ability to

<sup>1</sup>Clinical Associate Professor, Division of Periodontology, Department of Oral Medicine, Infection and Immunity, Harvard School of Dental Medicine, Boston, Massachusetts, USA.

<sup>2</sup>Chairman of the Master, School of Dentistry, Universidad Científica del Sur, Lima, Peru.

<sup>3</sup>Adjunct Professor, Department of Periodontology, University of Genoa, Genoa, Italy.

<sup>4</sup>Associate Professor, Division of Periodontology, Department of Oral Medicine, Infection and Immunity Harvard School of Dental Medicine, Boston, Massachusetts, USA.

Correspondence to: Dr David M. Kim, Division of Periodontology, Department of Oral Medicine, Infection and Immunity, Harvard School of Dental Medicine, 118 Longwood Avenue, Boston 02115, MA, USA.  
Email: dkim@hsdm.harvard.edu

©2018 by Quintessence Publishing Co Inc.

induce soft and hard tissue healing.<sup>9,10</sup> A cyanoacrylate tissue adhesive (Periacyrl 90, GluStitch) is known to be biocompatible and nontoxic for wound closure for up to 2 weeks. It has been used widely in dentistry for oral tissue adhesive applications and may play a protective role, with minimal contamination in cases with exposed collagen barrier membranes.

The objective of this clinical case series trial was to demonstrate the efficacy of cyanoacrylate tissue adhesive placed over an exposed collagen barrier membrane in conjunction with a bone graft substitute to enhance hard and soft tissue regeneration of an extraction wound.

## Materials and Methods

Fourteen patients requiring a socket preservation procedure (for a total of 25 extraction sockets) following extraction of single rooted teeth were enrolled and prepared for surgery in accordance with accepted dental practice guidelines including an informed consent form. The study protocol was approved by the IRB review board from the School of Dentistry, Universidad Científica del Sur, Lima, Peru. For all patients, radiographs were taken, and medical history and relevant demographic information were recorded. The following patient inclusion and exclusion criteria were implemented.

### *Inclusion Criteria*

1. Male or female patients in good health between 20 and 70 years of age requesting a dental implant treatment option for rehabilitation.
2. Subjects who were willing to sign an informed consent form, participate in the study, and return for follow-up visits.
3. Enclosed extraction site (without buccal wall defect).

### *Exclusion Criteria*

1. Subjects who did not meet all the inclusion criteria or who would not cooperate with the protocol schedule.
2. Subjects who had significant untreated periodontal disease, caries, infection, or chronic inflammation in the oral cavity within two adjacent tooth positions of the clinical trial area.
3. Subjects who had used nicotine-containing products within 3 weeks prior to surgery.
4. Subjects who were insulin-dependent diabetic or had Hgb1c levels > 6.5%.
5. Subjects who were nursing or pregnant.
6. Subjects who were presently taking medications (except estrogen/progesterone therapy) or those who were undergoing treatment that was known to have an effect on bone turnover.
7. Subjects who had diseases that affect bone metabolism (excluding idiopathic osteoporosis).

### *The Surgical Socket Preservation Procedure*

Surgical procedures were performed under local anesthesia on an outpatient basis. Complete clinical examinations, including radiographic examinations, were performed. Oral hygiene instructions were instituted and then reinforced at each clinical visit.

Horizontal full-thickness flaps were elevated on the buccal and palatal surfaces, with vertical incisions instituted for visibility if necessary. Atraumatic tooth extraction was performed, and cortical perforations were made with a pointed bur when there was inadequate bleeding. Mineralized cortical allograft (BaseBone, BaseBone Biologies) was delivered to the socket, and a collagen barrier membrane (Ossix Plus, Datum Dental) was contoured and inserted above.

Twenty augmented sites with various configurations of exposed membranes were treated with cyanoacrylate tissue adhesive (test group; Figs 1 to 3), while five augmented sites with exposed membranes did not receive this cyanoacrylate tissue adhesive (control group; Figs 4 and 5). Postsurgical visits included oral hygiene education reviews on a regular basis for 6 months. At that time, implant osteotomies were performed at select sites using a trephine bur for bone core biopsy, and the soft and hard tissues were photographed at all sites. Periapical radiographs of all implants were taken at the time of implant placement.

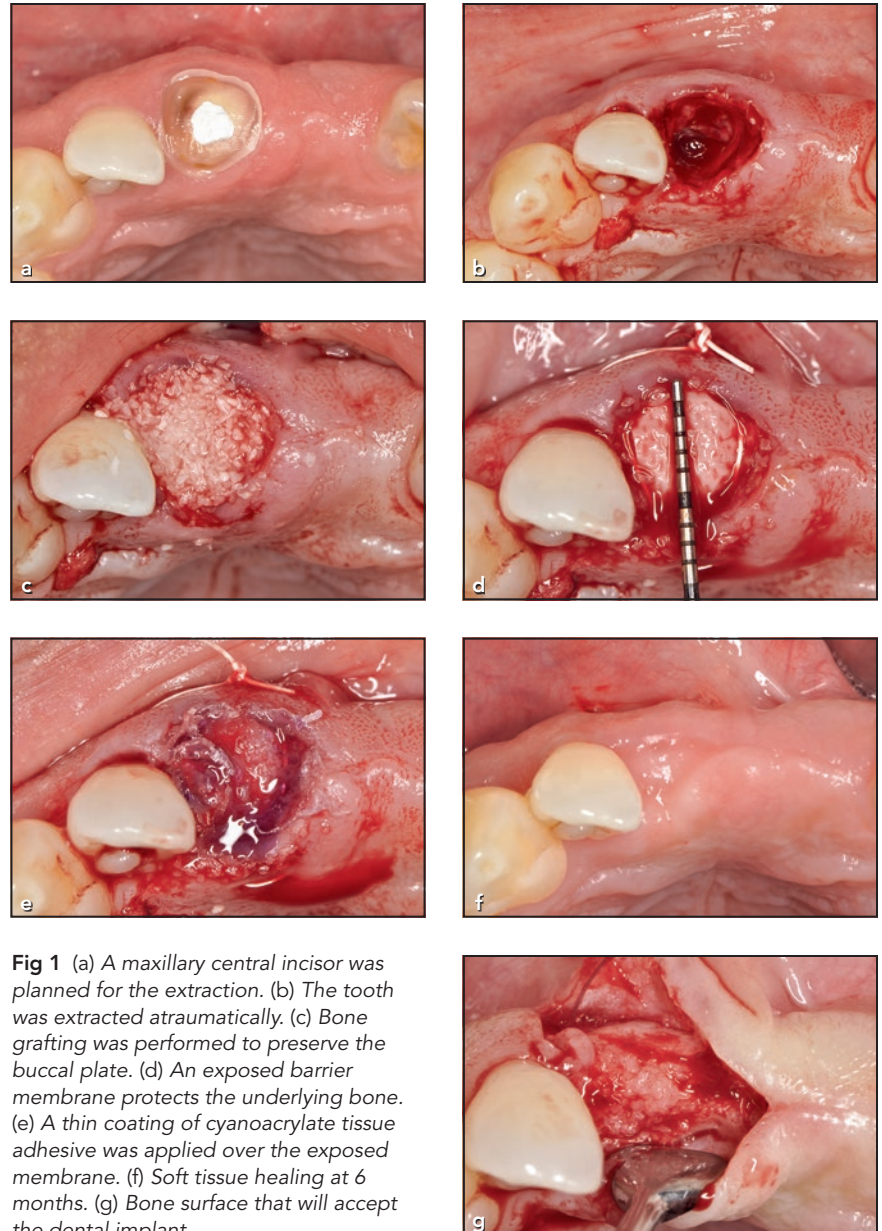
## Results

The goal of this clinical case series was to evaluate the efficacy of the application of a cyanoacrylate tissue adhesive in producing an optimal site for implant placement when positioned on an extraction wound. Eight out of the nine test patients completed the study. One test patient with two extraction socket preservation sites elected not to complete the study, and thus there were 18 socket augmentation procedures for the test group and 5 socket augmentation procedures for the control group.

The early phase of secondary wound healing in the test group was within the normal limits, without any signs of infection or other adverse events. When all extraction socket preservation areas were reexamined at 6 months, a normal soft tissue color and contour were noted for the test group and, upon bone exposure, a flat bone surface was noted (Figs 1f, 1g, 2f, 2g, 3e, and 3f). However, for the control group, the authors noticed several sites with minor soft and hard tissue concavities (Figs 4e, 4f, 5c, and 5d).

The test sites evident in Figs 1f, 1g, 2f, 2g, 3e, and 3f demonstrate soft and hard tissue forms that lend themselves to uncomplicated implant results. Although all healing sites allowed for dental implant placement, those treated with cyanoacrylate tissue adhesive presented an advantage compared to the control group.

Samples of the histologic results are shown in Figs 6 and 7. The patterns of bone formation for both



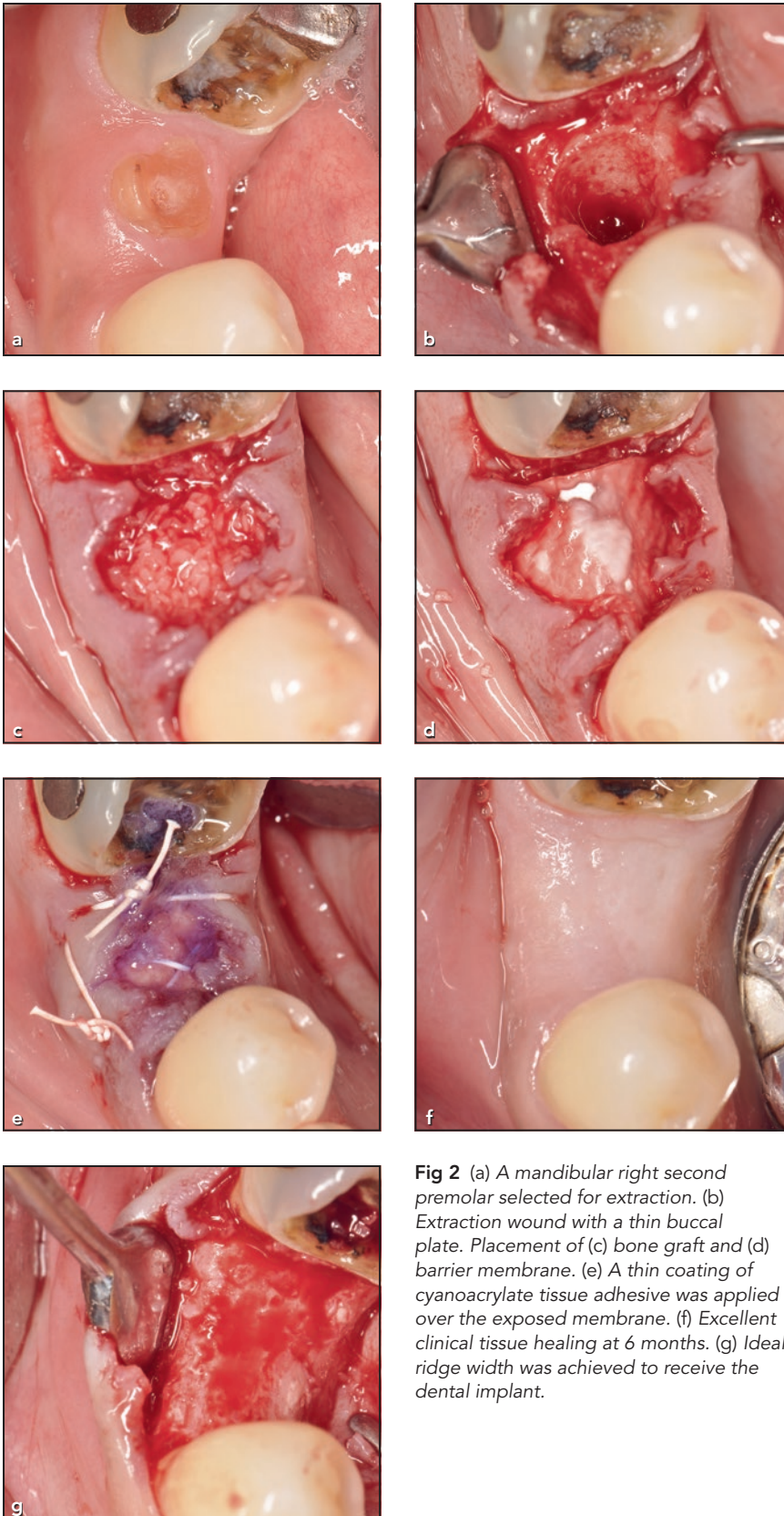
**Fig 1** (a) A maxillary central incisor was planned for the extraction. (b) The tooth was extracted atraumatically. (c) Bone grafting was performed to preserve the buccal plate. (d) An exposed barrier membrane protects the underlying bone. (e) A thin coating of cyanoacrylate tissue adhesive was applied over the exposed membrane. (f) Soft tissue healing at 6 months. (g) Bone surface that will accept the dental implant.

test and control sites, respectively, appeared to provide similar bone-to-implant contact, resulting in predictable implant stability.

## Discussion

Tooth extraction resulting from caries, fracture, root resorption, or

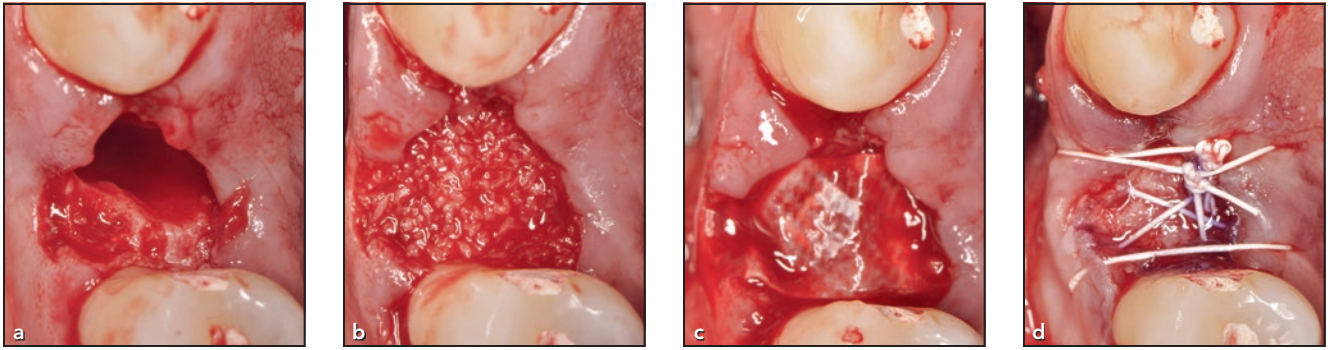
periodontal disease is a frequent event in most dental offices. Patients express concerns about esthetics, phonetics, and mastication and seek optimal results when discussing implant treatment. Dentists strive to achieve these results when augmenting the lost structure and benefit from the selection of widely available materials.



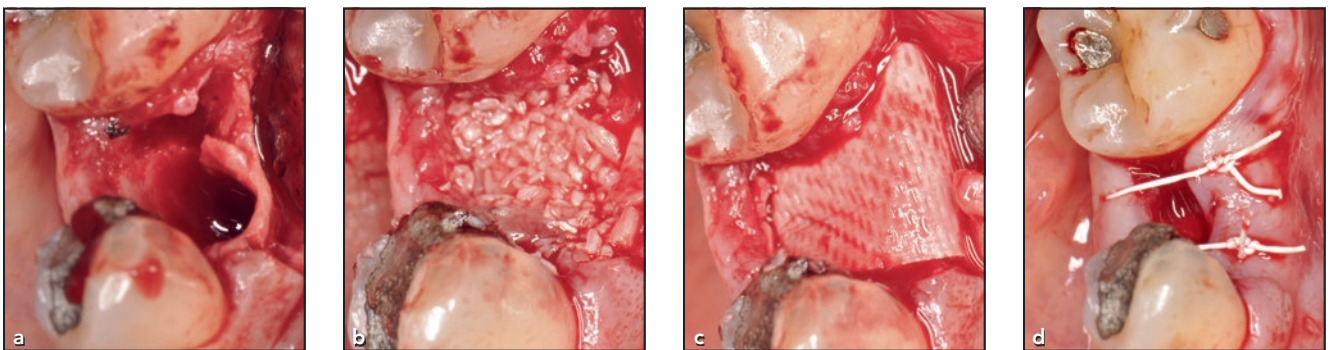
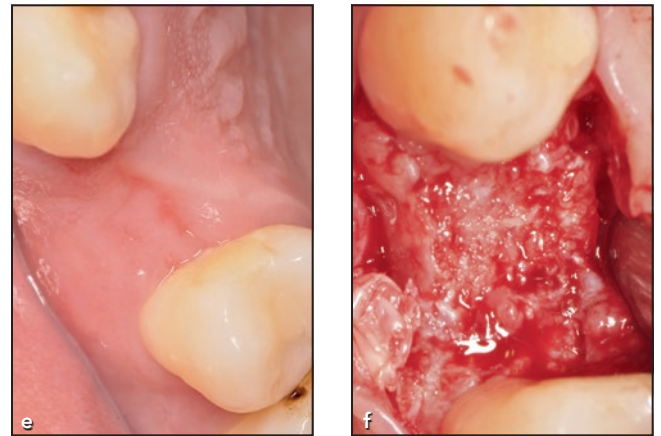
**Fig 2** (a) A mandibular right second premolar selected for extraction. (b) Extraction wound with a thin buccal plate. Placement of (c) bone graft and (d) barrier membrane. (e) A thin coating of cyanoacrylate tissue adhesive was applied over the exposed membrane. (f) Excellent clinical tissue healing at 6 months. (g) Ideal ridge width was achieved to receive the dental implant.

Contemporary treatment regimens have provided evidence that support plans for preservation of extraction sockets. There is a growing abundance of biomaterials and methods used to successfully protect the thin buccal plate for prominent teeth in a dental arch, as buccal bone has a very thin cortical nature that demonstrates resorption. The loss of this structure can result in compromised sites, especially if implants are in a buccal position. It has thus become appropriate to consider osseous rehabilitation of the socket with bone grafting and a barrier membrane. Primary wound healing frequently requires an altered position of the mucogingival junction or soft tissue contour, necessitating corrective surgery. The use of cyanoacrylate tissue adhesive provides an uncomplicated alternative to cover and protect the barrier membrane placed over the graft without repositioning. However, judicious use of the material is important to prevent the material from distorting the soft tissue.

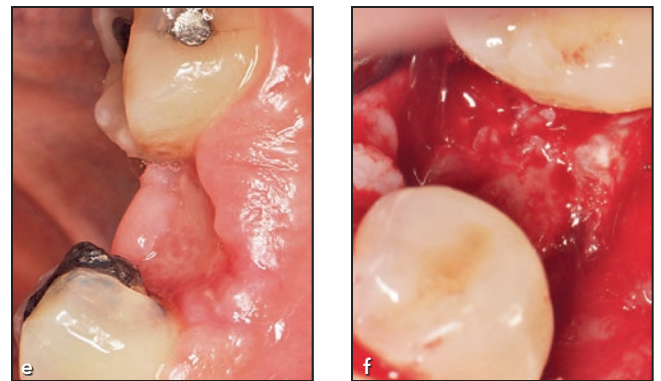
In 2011, GluStitch introduced PeriAcryl 90 High Viscosity, a thicker formulation to provide more control during application. This new product is nine times thicker than the original PeriAcryl 90 formulation and has the same strength and durability characteristics. It is very easy and convenient to use for oral tissue adhesive applications.

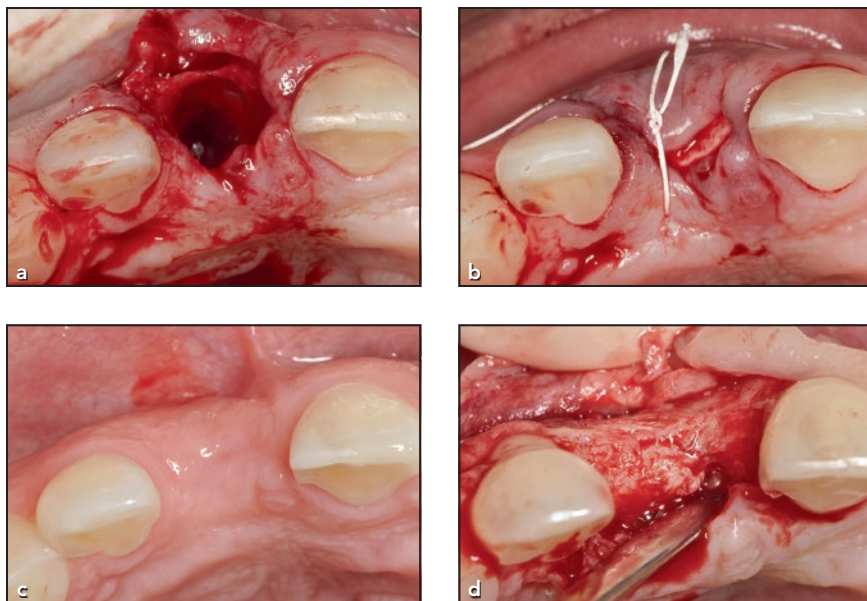


**Fig 3** (a) Atraumatic tooth extraction was performed. (b) A bone graft was placed to preserve the ridge. (c) Barrier membrane covering the underlying bone graft. (d) A thin coating of cyanoacrylate tissue adhesive was applied over the exposed membrane. (e) Excellent clinical tissue healing at 6 months. (f) Ideal ridge width was achieved to receive the dental implant.

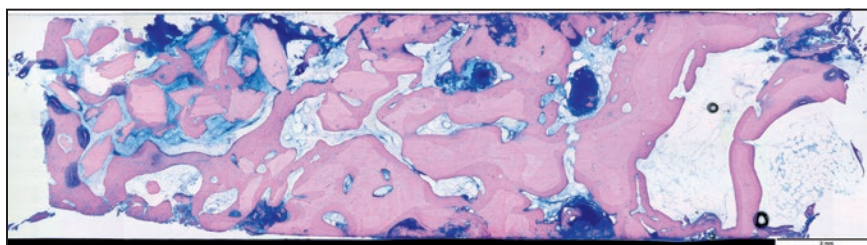


**Fig 4** (a) Thin buccal plate noted after atraumatic extraction. (b) Bone grafting was performed. (c) Barrier membrane was placed. (d) The surgical site was allowed to heal by secondary intention. (e) Healing at 6 months demonstrated suboptimal tissue contour. (f) Regenerated ridge at 6 months.

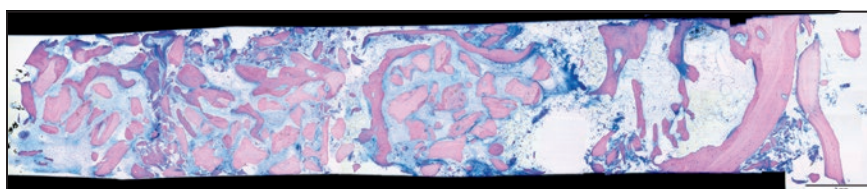




**Fig 5** (a) Atraumatic extraction revealing thin buccal plate. (b) Augmented site healing by secondary intention. (c) Postaugmentation procedure at 6 months. (d) Regenerated bone at 6 months.



**Fig 6** Light microscopic examination of a test site, revealing presence of new bone, remaining graft particles, and a connective tissue matrix.



**Fig 7** Light microscopic examination of a control site, revealing presence of new bone, remaining graft particles, and a connective tissue matrix.

## Conclusions

Cyanoacrylate tissue adhesive may play a beneficial role in protecting surgical wound sites that are undergoing secondary wound healing. This was a result of patient investigation

including 20 test sites and 5 control sites. All sites were able to receive dental implants, but tissue management was enhanced by the application of cyanoacrylate tissue adhesive.

## Acknowledgments

The funding for this report came from GluStich, Inc. The authors reported no conflicts of interest related to this study.

## References

1. Amler MH, Johnson PL, Salsman I. Histologic and histochemical investigation of human alveolar socket healing in undisturbed extraction wounds. *J Am Dent Assoc* 1960;61:46–48.
2. Lam RV. Contour changes of the alveolar process following extraction. *J Prosthet Dent* 1960;10:25–32.
3. Pietrokovski J, Massler M. Alveolar ridge resorption following tooth extraction. *J Prosthet Dent* 1967;17:21–27.
4. Mellonig JT, Nevins M, Sanchez R. Evaluation of a bioabsorbable physical barrier for guided bone regeneration. Part I. Material alone. *Int J Periodontics Restorative Dent* 1988;18:139–149.
5. Mellonig JT, Nevins M, Sanchez R. Evaluation of a bioabsorbable physical barrier for guided bone regeneration. Part II. Material and a bone replacement graft. *Int J Periodontics Restorative Dent* 1998;18:129–137.
6. Schropp L, Wenzel A, Kostopoulos L, Karning T. Bone healing and soft tissue contour changes following single-tooth extraction: A clinical and radiographic 12-month prospective study. *Int J Periodontics Restorative Dent* 2003;23:313–323.
7. Iasella JM, Greenwell H, Miller RL, et al. Ridge preservation with freeze dried bone allograft and a collagen membrane compared to extraction alone for implant site development. *J Periodontol* 2003;74:990–999.
8. Nevins M, Camelo M, De Paoli S, et al. A study of the fate of the buccal wall of extraction sockets of teeth with prominent roots. *Int J Periodontics Restorative Dent* 2006;26:19–29.
9. Kim DM, Nevins M, Camelo M, et al. The feasibility of demineralized bone matrix and cancellous bone chips in conjunction with an extracellular matrix membrane for alveolar ridge preservation: A case series. *Int J Periodontics Restorative Dent* 2011;31:39–47.
10. Kim DM, De Angelis N, Camelo M, Nevins ML, Schubach P, Nevins M. Ridge preservation with and without primary wound closure: A case series. *Int J Periodontics Restorative Dent* 2013;33:71–78.